

ARTICLE

Prospective Study of Centipede Bites in Australia

Corrine R. Balit, B.Pharm.,^{1,*} Mark S. Harvey, B.Sc., Ph.D.,²
Julianne M. Waldock, B.Sc.,² and
Geoffrey K. Isbister, B.Sc., M.B.B.S., F.A.C.E.M.¹

¹NSW Poisons Information Centre, The Children's Hospital at Westmead, Australia

²Department of Terrestrial Invertebrates, Western Australian Museum,
Perth, Western Australia, Australia

ABSTRACT

Background: There are limited reports of definite bites by centipedes with expert identification, which are required for attribution of particular clinical effects to different species. *Objective:* To describe the clinical effects of centipede bites in Australia. *Methods:* Prospective study of calls regarding centipede exposures to a state poison information center, from December 2000 to March 2002. Information collected included demographics, details of the exposure, local effects, systemic effects, and treatment. Collected centipedes were identified by an expert. All subjects were followed until clinical effects had resolved. *Results:* Of 48 centipede exposures, 3 were centipede ingestions with no adverse effects and one was a contact reaction to the centipede that resulted in erythema and delayed itchiness. Of 44 definite centipede bites, the centipedes obtained and formally identified in 14 cases were from the genera *Scolopendra* (5), *Cormocephalus* (6), and *Ethmostigmus* (3). Of these 14 bites, 13 occurred distally (hands or feet). Pain occurred in all 14 cases and was severe in 7 patients. Redness/red mark occurred in 53%, swelling/raised area in 43%, and itchiness in 14%. No systemic effects were reported. *Ethmostigmus* spp. and *Scolopendra* spp. caused more severe effects. Of the bites, 57% occurred indoors and 50% at night. Treatment consisted of supportive measures including ice packs and simple analgesia, and 4 patients reported pain relief after immersing the bite area in hot water. Similar

*Correspondence: Corrine R. Balit, B.Pharm., NSW Poisons Information Centre, The Children's Hospital, Locked Bag 4001, Westmead, NSW 2145, Australia; Fax: 61 2 9845 3597; E-mail: Corrinebalit@aol.com.

clinical effects were reported in the other 30 definite centipede bites. *Conclusions:* Australian centipede bites cause minor effects with moderate to severe pain, associated with localized swelling and erythema in bites by the genera *Ethmostigmus* and *Scolopendra*. Hot water immersion may potentially be beneficial for centipede bites. The genus *Scolopendra* occurs worldwide and the results may have international applicability.

Key Words: *Scolopendra*; Centipedes; PIC.

INTRODUCTION

Centipedes are readily identifiable arthropods that occur commonly in gardens and around houses. Calls to a poisons information center (PIC) regarding exposures to centipedes are reasonably common, particularly in the summer months. Although calls are not as frequent as for spider bites or bee and wasp stings, the number of centipede-related calls is similar to those for scorpions and caterpillars.

Centipedes belong to the class Chilopoda (1–3). Centipedes are widely distributed throughout the world (4). They are nocturnal creatures preferring dark, moist places. They range in length from 3 to 250mm long and have one pair of legs per body segment. The first pair of legs is modified into biting appendages called poison claws that discharge venom from an internal sac. The class includes more than 3000 known species classified into four orders (2). Members of two orders of centipedes are medically significant (1). Scolopendromorpha includes the most medically important centipedes, which occur in most parts of the world (1) and are characterized by their painful bites (1,5). The venoms of these centipedes have been the most commonly studied (6–8). Scutigermorpha, also known as ‘house or feather centipedes’ (1), have been reported to bite but are far less common.

There are limited reports of definite bites by centipedes and in only a few cases the centipedes were collected and identified by an expert (1,2,9–11). It is almost impossible to accurately attribute effects to different species without this strict case definition (12). Because of the few case reports and the many cases in which the centipede was only observed to bite, and considering the wide range in size and species of centipedes, any analysis of effects is based on grouping together very different reports. Thus, reported effects range from fatal cases in Thailand and the Philippines (13,14) to the majority of cases causing only minor effects such as local pain, redness, and swelling (15,16).

Centipede bites have been previously reported in Australia, but in many cases the centipede was not caught (1,4,9,17,18). In several Australian reviews of

centipede bites reference is made to a handful of cases reported to the authors (1,4,9,17,18), but there is still limited information on the bites by the major groups of centipedes, limiting the usefulness in clinical practice.

We conducted a prospective study to look at the clinical effects of centipede bites reported to a major PIC in Australia with expert identification of the centipedes when collection was possible.

METHODS

We conducted a prospective observational study of centipede exposures through the New South Wales (NSW) PIC from December 2000 until March 2002. NSW PIC is the largest PIC in Australia. It provides 24h poisons information to the general public and medical professionals and receives about 115,000 calls per year (19). There are approximately 140–160 calls relating to centipedes each year (Fig. 1).

Cases were identified from callers requesting advice regarding a centipede exposure (usually a bite). Verbal consent was obtained at the time of the call from the patient or the parent/guardian if the patient was a child (<16 years old). Subjects were interviewed over the phone either at the time of the call or within 24h. Subjects were followed up by phone and interviewed by

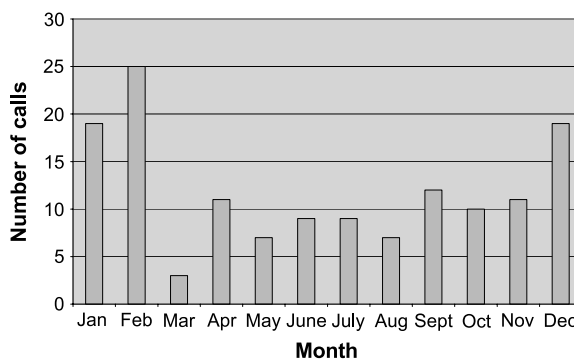


Figure 1. Number of centipede calls reported to the NSW poisons information center in 2001 (19). (View this art in color at www.dekker.com.)



either CRB or GKI until all clinical effects had resolved. Information collected included demographics (age, gender), relevant medical history, details of the exposure (activity at the time, location of the centipede), local effects (redness, swelling, pain severity and duration, itchiness), systemic effects, and treatment. Pain was defined as mild/moderate or severe, with severe being classified as worse than a bee sting.

Exposures were classified as a bite, contact only (no bite), or ingestion. Bites were further classified as definite or suspected, to allow better attribution of clinical effects of bites to centipede (12). A bite was classified as definite if the subject had a clear history of a bite, saw the centipede at the time, and there was objective evidence of the bite (immediate pain, bite marks, or bleeding at the site).

All centipedes that were caught at the time were mailed to the authors for identification. All identifications were performed by two authors (MH and JW) at the Western Australian Museum, following the taxonomy advocated by Koch (20–23). All specimens are lodged in the Western Australian Museum. Ethics approval was obtained from the ethics committee of The Children’s Hospital at Westmead.

RESULTS

There were 51 exposures to centipedes. Three patients were lost to follow up and excluded. There were 3 cases of centipede ingestion, and in one of these the partial remains of the centipede were available for identification. One patient had a contact reaction to a centipede that was subsequently collected for identification. The remaining 44 exposures were all definite bites from centipedes. Of these, 14 patients had caught the centipede, which was formally identified. Table 1 shows the identification of these centipedes, all belonging to the family Scolopendridae.

Centipede Bites with Identification

Of the 14 definite centipede bites in which the centipede was identified, there were 6 female and 8 male patients. Age ranged from 7 to 80 yrs with a median age of 46 yrs (IQR 13–56 yrs). Thirteen bites occurred distally on either the hands or feet. One patient was bitten in the axillary region. Pain occurred in all cases, with 7 patients reporting severe pain. Clinical effects are shown in Table 2. No systemic effects occurred in these 14 cases. Three patients presented to the hospital. The most common treatment

Table 1.

Genus	Number
<i>Scolopendra</i>	
<i>Scolopendra</i> spp.	3
<i>S. morsitans</i>	1
<i>S. laeta</i>	1
<i>Cormocephalus</i>	
<i>C. aurantiipes</i>	3
<i>C. westwoodi</i>	1
<i>C. monteithi</i>	1
<i>Cormocephalus</i> sp.	1
<i>Ethmostigmus</i>	
<i>E. rubripes</i>	3

was the application of ice or the use of simple oral analgesia. Four patients immersed the bite area in hot water, and 3 reported complete relief of the pain.

Scolopendra spp.

There were five bites by *Scolopendra* spp. Three bites occurred in the Northern Territory and all three patients experienced severe pain and presented to hospital. One of these patients requiring a small part of the centipede to be removed from the bite area. In the remaining two patients, the centipede was trodden on. Both patients experienced moderate pain and local redness. Four of the five patients received treatment, three had oral analgesia, and one patient’s foot was immersed in hot water, with complete resolution of symptoms within 30 min.

Cormocephalus spp.

There were six bites by *Cormocephalus* spp. (Fig. 2). Five of the six bites occurred distally (hand/feet) and one bite was to the axillary region. All six patients experienced pain, with only one reporting severe pain. Two patients experienced pain that radiated proximally. In five of the six patients pain lasted less than 2h and 7.5h in the other. Four patients had local redness and only one patient had evidence of local swelling. One patient reported complete relief with hot water immersion and one patient required oral analgesia.

Ethmostigmus spp.

There were three bites by *Ethmostigmus* spp. All three bites occurred distally (hand/feet). All three patients experienced severe pain lasting less than 3h.



Table 2.

	Centipede bites with positive identification N=14	Centipede bites not identified N=30
Age (median)	46 yrs (IQR 13–56)	29 yrs (IQR 11–47)
Gender	6 (43%)	21 (70%)
Location and time of bite:		
Indoors	8 (57%)	18 (60%)
Night (8pm–8am)	7 (50%)	15 (50%)
Activity at time of bite:		
Trod on	6 (43%)	7 (23%)
Sleeping	2 (13%)	4 (13%)
Cleaning	2 (13%)	2 (7%)
Gardening	1 (7%)	3 (10%)
Bathing/shower	0	6 (20%)
Other	3 (20%)	8 (27%)
Bite site:		
Distal (hands/feet)	13 (93%)	25 (83%)
Proximal limb	1 (7%)	4 (13%)
Trunk	0	1 (3%)
Pain:		
Mild/moderate	7 (50%)	24 (80%)
Severe	7 (50%)	6 (20%)
Radiation of pain	4 (27%)	4 (13%)
Total duration of pain (median)	30 min (3–120)	30 min (8–60)
Redness	8 (53%)	12 (40%)
Raised area/swelling	6 (43%)	13 (43%)
Itchiness		
Immediate	1 (7%)	5 (17%)
Delayed	1 (7%)	0
Systemic effects	0	2 (7%)
Treatment:		
Ice pack	8 (53%)	12 (40%)
Hot water	4 (27%)	3 (10%)
Analgesia	7 (47%)	3 (10%)

Two patients described pain radiating proximally. All three patients had local swelling, and two had local itchiness and redness. Two patients immersed the bite in hot water: one reported complete pain relief and one had partial relief.

Definite Centipede Bites Without Identification

Of the 30 centipede bites where the centipede was not available for identification, age ranged from 8 months to 75 yrs with a median age of 29 yrs (IQR 11–47). There were 21 female and 9 male patients. Twenty-five bites occurred on a distal part of the body (hands or feet). Pain occurred in all patients, and six patients reported severe pain. Clinical effects in this group were similar to those of the patients with confirmed identifications

(Table 2). Two patients reported nausea which settled without any treatment.

Centipede Ingestion

There were three cases of young children ingesting part of a centipede. In one case the remains of the centipede were available for expert identification. This case was an 8-month-old male who was found chewing on a centipede. The parents removed what was left (approximately half a centipede). The child was observed closely, but there were no other effects. The remains of the centipede were identified as *C. westwoodi*. In the other two cases a 9-month-old male and a 1-yr-old female were found with remains of centipedes in their mouths. They had no adverse effects. No centipede was available in these two cases.

Centipede Contact Reaction

In one patient there was a history more consistent with contact with the legs/spines of the centipede. They put their foot in a shoe, felt no pain at the time, but had a delayed onset of itchiness, erythema, and blue discoloration of the area. In addition there was a “spine” removed from the toe. This centipede was identified as *C. aurantiipes*. Effects resolved completely within seven days. No treatment was required.

DISCUSSION

Our study demonstrates that Australian centipede bites cause local pain and redness in the majority of cases. Bites were most often on distal limbs. There were no reports of severe systemic effects. This supports previous reports from other parts of the world, in particular in the Asia-Pacific region (15,16), that show that the majority of centipede bites cause minor effects. In addition we provide species-specific clinical effects for important groups of centipedes in Australia.

All identified centipedes were from the family Scolopendridae of the order Scolopendromorpha. These centipedes are the most easily recognized centipedes (1) and are large enough to bite through human skin. They range in color from shades of yellow, brown, red, green, blue, or even black (1). The Australian Scolopendridae consists of 40 named species in 9 genera, of which the genera *Scolopendra* (2 species), *Cormocephalus* (19 species), and *Ethmostigmus* (6 species) represent the most abundant and most commonly encountered centipedes.

Ethmostigmus rubripes is the largest of the common species found in Australia and has a wide distribution across mainland Australia; it is also known from Asia and some Pacific islands (23). *C. aurantiipes* is apparently endemic to Australia where it is most abundant in the southern half of mainland Australia, although sporadic records from northern Australia have been made (22). *S. morsitans* is a cosmopolitan species that is widespread in mainland Australia (21).

Pain was a universal feature of definite centipede bites. Severe pain occurred far more commonly with bites by *Ethmostigmus* spp. (100%) and *Scolopendra* spp. (60%), compared to *Cormocephalus* spp. (17%) (Fig. 2). The pain was mild/moderate in the majority of definite bites where no centipede was identified and may suggest that the majority of bites were by *Cormocephalus* spp. This may explain why in previous case reports more severe local and systemic effects have been attributed to centipede bites (1,17,24–26).




Figure 2. *Cormocephalus* centipede, Nightcliffe, Northern Territory, Australia. (View this art in color at www.dekker.com.)

Many of these reports describe severe intense pain following bites from the *Scolopendra* spp. consistent with our study. The minor effects of *Cormocephalus* bites may have never been previously reported, at least in Australia (1,5,27,28). Like many descriptions of bites and stings there is a bias to report more severe effects. Our series is more likely to reflect the true spectrum of effects seen with all types of centipede bites, because of the prospective collection of all definite centipede bites. It describes a similar spectrum of severity to the only other prospective study from Taiwan (15).

There have been reports of severe effects from centipede bites. Two deaths have been reported, where it is likely that the centipede was responsible for the death. The first was the death of a 7-yr-old child after being bitten on the head by a centipede (13). More recently the death of a 21-yr-old female in Thailand was reported following a centipede bite (14), although the effects in this case were more consistent with an early allergic reaction. Other more-severe effects include a report of Wells syndrome (25) following a centipede bite, although there are no details of the centipede. Wells Syndrome, also known as eosinophilic cellulitis, is an acute dermatitis resembling cellulitis, which evolves into plaques that resolve spontaneously



without scarring (29). Rhabdomyolysis and acute renal failure have been reported after a centipede bite from what the patient identified as a giant desert centipede, *S. heros*, from photographs (24). In our case series, there were no reports of serious systemic effects, including bites by *Scolopendra* spp. Two patients complained of nausea which settled without treatment.

There is one prospective study from Taiwan that reports minor effects in 31 cases (15), and an older study from the Andamans (16) which also showed a low frequency of severe local and systemic effects. Clinical effects vary enormously between different types (mainly genera) of centipedes from local effects, such as local pain, often severe in nature (1,5,26) to systemic effects (24,25), depending on the species of centipede involved.

Bites in this series occurred from three genera, which is likely to be representative of Australian centipedes. *E. rubripes* is the largest of the Australian centipedes, which is the likely reason that all three bites in our series caused severe pain, based on size alone. There is one previous report of a bite on the leg of an adult female that caused severe pain that lasted at least 4h (9). This was associated with significant erythema and swelling that lasted days. She had associated vomiting and diaphoresis on the first day, which resolved. Although there was a second episode of swelling, this was more likely a result of secondary infection (9). McKeown reports the death of a 4-yr-old bull-terrier following a bite by *E. rubripes* (4). Reports in northern Australia of large centipedes whose bites cause severe pain sometimes with associated systemic effects are possibly due to *E. rubripes* (1), although in this study all three bites from the Northern Territory were *Scolopendra* spp. Other genera of large centipedes, such as *Rhysida* and *Otostigmus* occur in the tropics. The three definite bites by *E. rubripes* in this study also caused more severe effects than other centipedes with all patients reporting severe pain and local swelling, and in two cases radiation of the pain.

The genus *Scolopendra* occurs worldwide with a number of reports from the Asia-Pacific region, Australia, and the United States (1,11,16,24,26,27,30). The genus is probably responsible for many of the more-severe effects reported in tropical regions, although in the majority of cases they are likely to cause less-severe effects. Southcott reports two cases of *Scolopendra* spp. bites in which pain at the bite site was the predominant feature. One patient experienced nausea lasting for a week, which is an unusual effect in isolation and difficult to attribute to venom or bite mediated effects. There were no other adverse effects reported. We report a further five cases by this cen-

tipede that caused severe pain in three cases, all of which occurred in the Northern Territory. There were no reports of systemic effects.

The commonest genus to cause bites in this series, where the centipede was caught, was *Cormocephalus*, which have not previously been reported. The genus is found in many parts of the world but principally in warmer climatic zones (22). In our series these centipedes caused less severe effects with only one case of severe pain. Local erythema occurred in 67% of the cases with swelling in only one (17%) case. In the majority of the cases, the pain was short-lived and analgesia was not required.

Ingestion of centipedes is not commonly reported. There is one report of a young child ingesting a centipede in Australia resulting in the child appearing pale, floppy, and lethargic (31). The centipede was identified as being from the order *Scutigermorpha*. In this study there were three children who ingested centipedes and in one case the centipede was available for identification. This centipede was from the order *Scolopendromorpha*, different to the reported case report (31). In all three cases there were no adverse effects.

It is well known that some arthropods, in particular hymenoptera, can cause severe early allergic reactions following stings (32). However, not all insects are reported to cause hypersensitivity reactions; for example, there is good evidence that spider bites do not cause allergic reactions (33). It is possible that centipedes may produce venoms that have immunogenic properties, and one fatality reported is consistent with a Type IV systemic allergic reaction (14). In addition, based on this study and previous reports swelling appears to be a prominent feature in many centipede bites (1,2), which similar to bee and wasp stings (34) more than spider bites or scorpion stings (33,35). It could thus be postulated that components of centipede venoms are able to induce local inflammatory reactions and potentially more generalized hypersensitivity reactions. This would need to be confirmed in studies of the venom and large epidemiological studies of centipede bites and exposure.

In one case the clinical effects were similar to that of contact with [a part of] the centipede and not an actual bite. The patient suffered no pain at the time. Instead they had significant delayed itchiness and erythema, associated with a "spine" at the site, more consistent with a foreign body reaction. This has been previously reported with injuries from spider spines, where the spines of the forelegs of the spider break off on contact and can result in itchiness and redness at the site (36). There have been previous reports of wheal formation after skin contact with the legs of centipedes (37).



However, details of these exposures are limited and no identification of the centipede was recorded.

There is currently little information on appropriate treatment for centipede bites. There have been several anecdotal reports describing various treatment options, such as local application of ammonia (38) and oral cortisone therapy (39). In our series, the effects of centipede bites appeared to settle with the application of ice and simple analgesia, such as paracetamol. Interestingly, several patients reported a benefit with immersion of the bite area in hot water. Hot water immersion has previously been shown to be effective in marine stings (40,41), and there is one report of hot water application being effective for centipede bites (30). This would need further investigation in controlled trials.

A limitation of our study was that patients were not examined, but care was taken to use a standardized form to record the effects. The study used recently recommended methodology for studies in clinical toxicology (12) with prospective data collection, follow-up of all cases, and collection and expert identification of centipedes. Although centipedes were only available in a third of cases the remaining cases were only included if there was clear evidence of a definite bite, including a sighting of the centipede. It could be argued that only cases with creature identification should be included, and this was the reason for the separate analysis of cases. However, centipedes are large, reasonably slow moving creatures with a characteristic appearance. Thus, it is likely that using carefully defined criteria for inclusion meant that the other 30 cases were almost certainly the result of centipede bites.

The study recruited cases using calls to a PIC rather than presentations to an emergency department. This allowed for recruitment of larger numbers of cases and the inclusion of a wider spectrum of severity, because minor bites and stings are less likely to be seen in an emergency department or hospital.

CONCLUSIONS

Centipede bites, although a common occurrence during summer in Australia, appear to result in minor local effects. A large number of bites occurred indoors and in half of the definite cases with identification, the centipede was trodden on. Larger species cause more severe pain, and a higher incidence of swelling. The symptoms appear to settle with ice and simple analgesia. Immersion of the bite area in hot water appeared to result in pain relief. Further studies are required to look at different treatment modalities.

ACKNOWLEDGMENTS

We would like to thank all the staff at the NSW Poisons Information Centre for their help and assistance in recruiting cases. We also thank Dr. Mike Gray for providing the identification of three of the centipedes.

REFERENCES

1. Southcott RV. Arachnidism and allied syndromes in the Australian region. *Rec Adel Child Hosp* 1976; 1(1):97–186.
2. Minelli A. Secretions of centipedes. In: Bettini S, ed. *Arthropod Venoms*. Berlin: Springer-Verlag, 1978:73–85.
3. Harvey MS, Yen AL. *Worms to Wasps: An Illustrated Guide to Australia's Terrestrial Invertebrates*. Melbourne: Oxford University Press, 1989.
4. McKeown KC. Centipedes and centipede bites. *Aust Mus Mag* 1930; 4(2):59–60.
5. Mumcuoglu KY, Leibovici V. Centipede (*Scolopendra*) bite: a case report. *Isr J Med Sci* 1989; 25(1):47–49.
6. Gomes A, Datta A, Sarangi B, Kar PK, Lahiri SC. Pharmacodynamics of Venom of the Centipede *Scolopendra subspinipes dehaani* Brandt. *Ind J Exp Biol* 1982; 20:615–618.
7. Mohamed AH, Abu-Sinna G, El-Shabaka HA, Abd El-Aal A. Proteins, lipids, lipoproteins and some enzyme characterizations of the venom extract from the centipede *Scolopendra morsitans*. *Toxicon* 1983; 21(3):371–377.
8. Mohamed AH, Zaid E, El-Beih NM, Abd El-Aal A. Effects of an extract from the centipede *Scolopendra morsitans* on intestine, uterus and heart contractions and on blood glucose and liver and muscle glycogen levels. *Toxicon* 1980; 18:581–589.
9. Sutherland SK, Tibballs J. *Australian Animal Toxins*. 2nd ed. Melbourne: Oxford University Press, 2001.
10. Gelbier S, Kopkin B. Pericoronitis due to a centipede: a case report. *Br Dent J* 1972; 133:307–308.
11. Rodriguez-Acosta A, Gassette J, Gonzalez A, Ghisoli M. Centipede (*Scolopendra gigantea* Linnaeus 1758) envenomation in a newborn. *Rev Inst Med Trop Sao Paulo* 2000; 42(6):341–342.
12. Isbister GK. Data collection in clinical toxicology: debunking myths and developing diagnostic algorithms. *J Toxicol Clin Toxicol* 2002; 40(3):231–237.

13. Pineda EV. A fatal case of centipede bite. *J Med Assoc* 1923; 3:59–61.
14. Severe Hypotension and Adult Respiratory Distress Syndrome (ARDS) following centipede bite. From the Proceedings of the 5th Asia Pacific Congress on Animal, Plant and Microbial Toxins, 1999.
15. Lin TJ, Yang CC, Yang GY, Ger J, Tsai WJ, Deng JF. Features of centipede bites in Taiwan. *Trop Geogr Med* 1995; 47(6):300–302.
16. Uppal SS, Agnihotri V, Ganguly S, Badhwar S, Shetty KJ. Clinical aspects of centipede bite in the Andamans. *J Assoc Phys India* 1990; 38(2):163–164.
17. Cleland JB. Injuries and disease in Australia attributable to animals (other insects) (series IV). *Med J Aust* 1932; 1:157–166.
18. Lee D. Arthropod Bites and Stings and Other Injurious Effects. School of Public Health and Tropical Medicine, The University of Sydney: Sydney, 1975.
19. NSW Poisons Centre Annual report. 2001.
20. Koch LE. Taxonomy of the centipede genus *Scolopendra laeta* Haase (Chilopoda: Scolopendridae) in Australia. *Zool J Linn Soc* 1982; 76:125–140.
21. Koch LE. Morphological characters of the Australian scolopendrid centipedes, and the taxonomy and distribution of *Scolopendra morsitans* L. (Chilopoda: Scolopendridae: Scolopendrinae). *Aust J Zool* 1983; 31:79–91.
22. Koch LE. Revision of the Australian centipedes of the genus *Cormocephalus* Newport (Chilopoda: Scolopendridae: Scolopendrinae). *Aust J Zool* 1983; 31:799–833.
23. Koch LE. A taxonomic study of the centipede genus *Ethmostigmus* Pocock (Chilopoda: Scolopendridae: Otostigminae) in Australia. *Aust J Zool* 1983; 31:835–849.
24. Logan JL, Ogden DA. Rhabdomyolysis and Acute Renal Failure following the bite of the giant desert centipede *Scolopendra heros*. *West J Med* 1985; 142(4):549–550.
25. Friedman IS, Phelps RG, Baral J, Sapadin AN. Wells' syndrome triggered by a centipede bite. *Int J Dermatol* 1998; 37(8):602–605.
26. Mohri S, Sugiyama A, Saito K, Nakajima H. Centipede bites in Japan. *Cutis* 1991; 47:189–190.
27. Knysak I, Martins R, Bertim CR. Epidemiological aspects of centipede (Scolopendromorphae: Chilopoda) bites registered in Greater S. Paulo, SP, Brazil. *Rev Saude Publica* 1998; 32(6):514–518.
28. Martin CM. Scorpions and centipedes of the Hawaiian Islands: their medical significance. *Hawaii Med J* 1971; 30(2):95–98.
29. Moossavi M, Mehregan D. Wells' syndrome: a clinical and histopathologic review of seven cases. *Int J Dermatol* 2003; 42(1):62–67.
30. Bush SP, King BO, Norris RL, Stockwell SA. Centipede envenomation. *Wilderness Environ Med* 2001; 12:93–99.
31. Barnett PLJ. Centipede ingestion by a six-month-old infant: toxic side effects. *Pediatr Emerg Care* 1991; 7(4):229–230.
32. Brown SGA, Franks RW, Baldo BA, Heddle RJ. Prevalence, severity, and natural history of jack jumper ant venom allergy in Tasmania. *J Allergy Clin Immunol* 2003; 111(1):187–192.
33. Isbister GK, Gray MR. A prospective study of 750 definite spider bites, with expert spider identification. *QJM* 2002; 95(11):723–731.
34. Balit CR, Isbister GK, Buckley NA. Randomised controlled trial of topical aspirin in the treatment of bee and wasp stings. *J Toxicol Clin Toxicol*. In press.
35. Isbister GK, Volschenk ES, Balit CR, Harvey MS. Australian Scorpion Stings: a prospective study of definite stings. *Toxicon*. In press.
36. Isbister GK, Hirst D. Injuries from spider spines, not spider bites. *Vet Hum Toxicol* 2002; 44(6):339–342.
37. Lawrence RF. The centipedes and millipedes of southern Africa. A guide. Cape Town and Rotterdam, 1984.
38. Blay ER. Treatment of centipede bites. *BMJ* 1955; 1619.
39. Ariff AW. Cortisone for centipede bites. *BMJ* 1956:986.
40. Carrette TJ, Cullen P, Little M, Peiera PL, Seymour JE. Temperature effects on box jellyfish venom: a possible treatment for envenomed patients? *Med J Aust* 2002; 177(11/12):654–655.
41. Kizer KW, McKinney HE, Auerbach PS. Scorpaeidae envenomation. A five-year poison center experience. *JAMA* 1985; 253(6):807–810.

Submitted July 1, 2003
 Accepted August 7, 2003

Request Permission or Order Reprints Instantly!

Interested in copying and sharing this article? In most cases, U.S. Copyright Law requires that you get permission from the article's rightsholder before using copyrighted content.

All information and materials found in this article, including but not limited to text, trademarks, patents, logos, graphics and images (the "Materials"), are the copyrighted works and other forms of intellectual property of Marcel Dekker, Inc., or its licensors. All rights not expressly granted are reserved.

Get permission to lawfully reproduce and distribute the Materials or order reprints quickly and painlessly. Simply click on the "Request Permission/Order Reprints" link below and follow the instructions. Visit the [U.S. Copyright Office](#) for information on Fair Use limitations of U.S. copyright law. Please refer to The Association of American Publishers' (AAP) website for guidelines on [Fair Use in the Classroom](#).

The Materials are for your personal use only and cannot be reformatted, reposted, resold or distributed by electronic means or otherwise without permission from Marcel Dekker, Inc. Marcel Dekker, Inc. grants you the limited right to display the Materials only on your personal computer or personal wireless device, and to copy and download single copies of such Materials provided that any copyright, trademark or other notice appearing on such Materials is also retained by, displayed, copied or downloaded as part of the Materials and is not removed or obscured, and provided you do not edit, modify, alter or enhance the Materials. Please refer to our [Website User Agreement](#) for more details.

[Request Permission/Order Reprints](#)

Reprints of this article can also be ordered at

<http://www.dekker.com/servlet/product/DOI/101081CLT120028743>